

Changes of vision and refraction in patients with thyroid pathology

Jūratė Jankauskienė, Vaida Jakštaitė¹, Vilmantas Smalinskas¹

Department of Eye Diseases, Kaunas University of Medicine, ¹Kaunas University of Medicine, Lithuania

Key words: thyrotoxicosis; thyroid pathology; exophthalmos; myopia; visual acuity.

Summary. Objective. The aim of the study was to assess the relationship between thyroid pathology and visual acuity, including refraction disorders.

Material and methods. The data of visual acuity, refraction, and exophthalmos were analyzed, which were obtained from 105 patients with thyroid pathology. The data were compared with the findings of 23 healthy persons of similar age (control group).

Results. In case of thyroid pathology, visual acuity (right eye 0.71 ± 0.035 , left eye 0.73 ± 0.045) was worse than in the control group (right eye 0.89 ± 0.06 , $P < 0.05$; left eye 0.92 ± 0.07 , $P < 0.05$). Myopia dominated in patients with thyroid pathology (refraction: right eye $M 1.1 \pm 0.61$ D, left eye $M 1.0 \pm 0.64$ D). In patients with exophthalmos of ≥ 17 mm, visual acuity was significantly worse (right eye 0.68 ± 0.04 , left eye 0.68 ± 0.03) than in persons of the control group (right eye 0.89 ± 0.06 , $P < 0.05$; left eye 0.92 ± 0.07 , $P < 0.05$), and myopic refraction was found more frequently (right eye $M 1.3 \pm 0.48$ D, left eye $M 1.3 \pm 0.56$ D). Visual acuity was significantly better in patients when exophthalmos was < 17 mm (right eye 0.80 ± 0.05 , $P < 0.05$; left eye 0.80 ± 0.05 , $P < 0.05$) than in cases when exophthalmos was ≥ 17 mm.

Conclusions. Thyroid pathology and exophthalmos have an influence on visual acuity and refraction. In case of thyroid pathology, visual acuity appears to be worse than in the control group, and myopic refraction is more frequent. Visual acuity was found to be worse in patients with exophthalmos being ≥ 17 mm than in the control group, and myopic refraction was found to be more frequent.

Introduction

Thyroid diseases have been diagnosed in 2 of 10 persons of Lithuanian population (they occur more often than diabetes mellitus and cancer taken together). Due to the fact that symptoms of thyroid diseases are commonly taken as natural features of aging, the real cause of such ailments often remains unidentified.

Patients with thyroid disease (thyrotoxicosis, diffuse or nodular goiter) can manifest different eye lesions: exophthalmos, changes in vision and refraction characterised by a multifactor mechanism of development.

Proliferation of retrobulbar cells (fatty and connective tissue cells, lacrimal gland cells) and their infiltration with lymphocytes, plasmic cells, macrophages, mucopolysaccharides and the excretion of various inflammatory factors as well as an increased extent of extraocular muscles have an influence on the development of exophthalmos (1–3).

There is a close relationship between thyroid function and metabolism in the muscles, with thyroid hormones effecting tonicity of muscles (1, 3). Muscular

tonicity increases because thyroid hormones intensify the synthesis of enzymes, which catalyze oxidation reactions. Under the effect of iodothyronines, there is an increase in the number of mitochondria in cells, the process of oxidative phosphorylation is intensified, leading to the production of greater amounts of ATP that facilitate the process of metabolism (3–6).

Patients with thyrotoxicosis associated with an increase in muscular tonicity can develop tachycardia, atrial fibrillation, accentuated heart sounds (6, 7), changes of thyroid volume (8), trembling of hands, diarrhea, positive Rosenbach's sign (tremor of the eyelids), positive Graefe's and Dalrymple's (widened palpebral aperture) signs because of increased tonicity of levator muscle of the upper eyelid (2, 9, 10). In the case of hypothyreosis, bradycardia, obstipation, and hypodynamia may occur.

It has been established that the receptors of thyroid hormones are present almost in all tissues and organs of the body except the brain, spleen, and testicles (6, 11), so it is quite credible that tonicity of ciliary muscles (smooth fibers) also depends on the activity of

thyroid gland. That is why hyperthyreosis can cause refraction alterations, mostly those of myopia.

This proposition is confirmed by the fact that in the presence of resistance to thyroid hormones, when thyroid hormone level increases due to mutation of receptors of thyroid hormones, the patients under study were diagnosed as having myopia (12, 13).

Refraction changes might be affected by the immune complexes accumulated on the lateral walls of the orbit and by enlarged volume of the motor muscles of eyeball (14). Then, under pressure, the eyeball undergoes remodeling with the longitudinal ocular axis growing longer. It has been established experimentally that when optical axis lengthens by 1 mm, myopia increases by 3 D (15).

Weakening of visual acuity is induced by optic nerve neuropathy caused by the thickening of rectal eye muscles (16) and the pressure exerted by the optic nerve at the orbital apex (10, 17, 18).

The aim of this study was to assess the influence of thyroid pathology and exophthalmos on visual acuity and refraction.

Material and methods

The data of visual acuity, refraction, and exophthalmos were analyzed in patients with thyroid pathology. There were 105 persons (10 men and 95 women) with thyroid pathology, and thyroid hyperfunction was diagnosed in the majority of cases. The age of the patients varied from 21 to 87 years. The mean age was 49 ± 4.5 years. The data were compared with the data of control group obtained from 23 healthy persons (without thyroid pathology) of similar age.

Data processing was done using the Statistical Package for the Social Sciences (SPSS). Mann-Whitney test was used for comparisons of differences. The data are given with root-mean-square-error (RMSE) indices. The differences were considered as statistically significant if $P\leq 0.05$.

Results

The results showed that in the case of thyroid pathology, visual acuity in the right eye (OD) was 0.71 ± 0.035 , and in the left eye (OS), it was 0.73 ± 0.045 . It was worse than in the control group (OD 0.89 ± 0.06 , $P<0.05$; OS 0.92 ± 0.07 , $P<0.05$) (Fig. 1).

Myopia (M) dominated in patients with thyroid pathology (refraction: OD M 1.1 ± 0.61 D, OS M 1.0 ± 0.64 D).

Visual acuity was significantly worse in the patients with exophthalmos of ≥ 17 mm (OD 0.68 ± 0.04 ,

OS 0.68 ± 0.03) than in the control group (OD 0.89 ± 0.06 , $P<0.05$; OS 0.92 ± 0.07 , $P<0.05$).

Myopic refraction was diagnosed more often in patients with exophthalmos of ≥ 17 mm (OD M 1.3 ± 0.48 D, OS M 1.3 ± 0.56 D). Visual acuity was significantly better in patients when exophthalmos was < 17 mm (OD 0.80 ± 0.05 , $P<0.05$; OS 0.80 ± 0.05 , $P<0.05$) than in cases when exophthalmos was ≥ 17 mm (Fig. 2).

Discussion

We have not found the same studies on the influence of thyroid pathology on the development of myopia and visual acuity impairment; therefore, we compared our results with those of similar studies. Phillips et al. and Frank-Raue et al. (2004) reported that the excess of thyroid hormones caused by mutation of receptors of thyroid hormones had an influence on the development of myopia (12, 13). According to the findings of our study, myopia dominated in patients showing refraction (OD M 1.1 ± 0.61 D, OS M 1.0 ± 0.64 D), besides we have also found that patients with thyroid pathology had worse visual acuity (OD 0.71 ± 0.035 , OS 0.73 ± 0.045) than those in the control group (OD 0.89 ± 0.06 , $P<0.05$; OS 0.92 ± 0.07 , $P<0.05$).

Saw et al. (2002) and Drexler et al. (1998) indicated that myopia degree directly depended on the length of the optical axis (19, 20). According to the results of our study, myopic refraction occurred more often in patients with exophthalmos of ≥ 17 mm (OD M 1.3 ± 0.48 D, OS M 1.3 ± 0.56 D).

Besides, visual acuity was found to be significantly better in the patients whose exophthalmos was less prominent (OD 0.80 ± 0.05 , $P<0.05$; OS 0.80 ± 0.05 , $P<0.05$) than in patients with more expressed exophthalmos.

Comparing the results of our study and literature data, the same tendencies have been observed. In cases of thyroid pathology, visual acuity and refraction changes develop due to proliferation of retrobulbar cells, causing exophthalmos (14, 15). One of the reasons of myopia development is eyeball remodeling, along with thyroid hormones affecting the tonicity of ciliary muscle (5, 9, 10).

Conclusions

The findings of our study showed that thyroid pathology and exophthalmos have an influence on visual acuity and refraction:

1. In the case of thyroid pathology, visual acuity appeared to be worse than in the control group, and

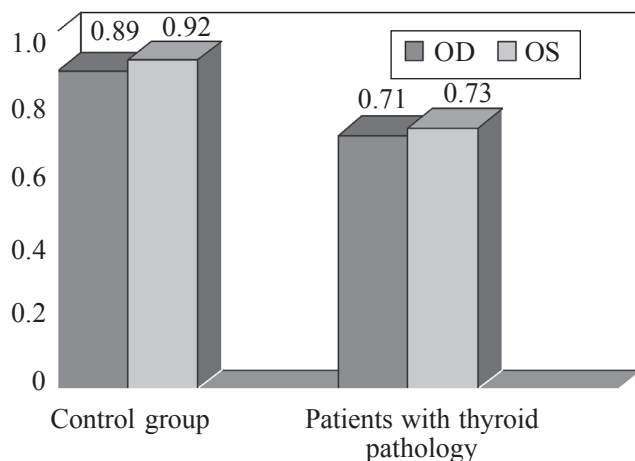


Fig. 1. Comparison of visual acuity in patients with thyroid pathology and control group

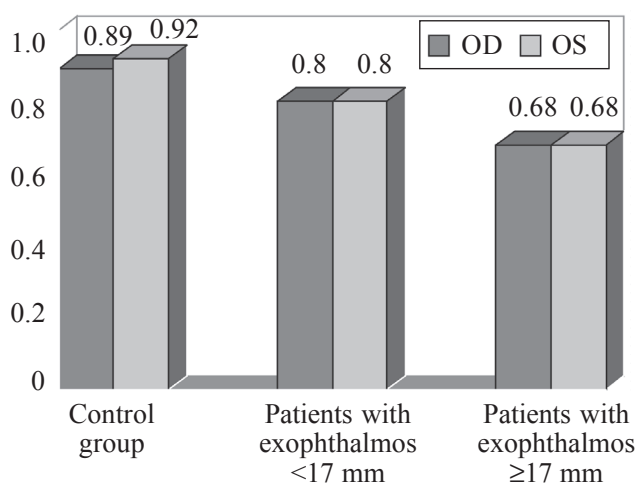


Fig. 2. Comparison of visual acuity in patients with exophthalmos (<17 mm, ≥17 mm) and control group

- myopic refraction was seen more frequently;
- Visual acuity was found to be worse in patients with exophthalmos being ≥ 17 mm than in the control group, and myopic refraction was found to be
 - more frequent;
 - Visual acuity is significantly better in patients with exophthalmos being < 17 mm than in patients with exophthalmos of ≥ 17 mm.

Regėjimo ir refrakcijos pokyčiai esant skydliukės patologijai

Jūratė Jankauskienė, Vaida Jakštaitė¹, Vilmantas Smalinskas¹

Kauno medicinos universiteto Akių ligų klinika, ¹Kauno medicinos universitetas

Raktažodžiai: tireotoksikozė, skydliukės patologija, išverstakumas, trumparegystė, regėjimo aštrumas.

Santrauka. *Tyrimo tikslas.* Įvertinti ryšį tarp skydliukės patologijos ir regos aštrumo bei refrakcijos pokyčių. *Medžiaga ir metodai.* Analizavome šiuos tiriamųjų duomenis: regos aštrumą, refrakciją ir išverstakumą. Analizuoti duomenys surinkti iš skydliukės patologija sergančių 105 pacientų, kurie lankėsi KMUK Akių ligų klinikoje. Tyrimo duomenys lyginti su panašaus amžiaus 23 sveikų asmenų (kontrolinė grupė) analogiškais duomenimis.

Rezultatai. Sergančiųjų skydliaukės patologija regos aštrumas (dešinės akies – $0,71 \pm 0,035$, kairės – $0,73 \pm 0,045$) buvo prastesnis nei kontrolinės grupės (dešinės akies – $0,89 \pm 0,06$, $p < 0,05$; kairės – $0,92 \pm 0,07$, $p < 0,05$). Tiriamiesiems dominavo trumparegystė: dešinė akis M $1,1 \pm 0,61$ D, kairė – M $1,0 \pm 0,64$ D). Pacientams, kurių išverstakumas ≥ 17 mm, regos aštrumas buvo reikšmingai mažesnis (dešinė akis $0,68 \pm 0,04$, kairė – $0,68 \pm 0,03$) nei kontrolinės grupės (dešinė – $0,89 \pm 0,06$, $p < 0,05$; kairė – $0,92 \pm 0,07$, $p < 0,05$), jiems dažniau nustatyta trumparegystės refrakcija (dešinė akis M $1,3 \pm 0,48$ D, kairė – M $1,3 \pm 0,56$ D). Tiriamųjų, kurių išverstakumas < 17 mm, regos aštrumas (dešinės akies – $0,80 \pm 0,05$, $p < 0,05$; kairės – $0,80 \pm 0,05$, $p < 0,05$) statistiškai reikšmingai didesnis, nei esant išverstakumui ≥ 17 mm.

Išvados. Skydliaukės patologija bei išverstakumas turi įtakos regėjimo aštrumui bei refrakcijai. Esant skydliaukės patologijai, regos aštrumas mažesnis nei kontrolinės grupės tiriamųjų, be to dažnesnė trumparegystės refrakcija. Tiriamiesiems, kurių išverstakumas ≥ 17 mm, regos aštrumas statistiškai reikšmingai mažesnis nei kontrolinės grupės tiriamųjų, taip pat dažniau nustatyta trumparegystės refrakcija.

Adresas susirašinti: J. Jankauskienė, KMU Akių ligų klinika, Eivenių 2, 50009 Kaunas
El. paštas: j_jankauskiene@yahoo.com

References

- Lapinskas V. Skydliaukės ligos. (Thyroid diseases.) Vilnius: Mokslas; 1991. p. 13, 26-31.
- Jankauskienė J. Akiduobės ligos. (Orbital diseases.) Kaunas: KMU; 2003. p. 156-7.
- Veličkienė D, Kazanavičius G, Danilevičius J, Jankauskienė J. Endokrininės oftalmopatijos gydymo jonizuojančiąja spinduliuote efekto prognozavimo tyrimas. (Predicting outcome of treatment with radiotherapy in endocrine ophthalmopathy.) *Medicina (Kaunas)* 2007;43(3):190-8.
- Praškevičius A, Ivanovienė L, Stasiūnienė N, Burneckienė J, Rodovičius H, Lukoševičius L, et al. *Biochemija*. (Biochemistry.) Kaunas: KMU; 2003. p. 602-03.
- Drebickas V. Vidaus sekrecijos liaukų fiziologija. (Physiology of endocrine glands.) Vilnius: UAB „Nevėžio spaustuvė“; 2000. p. 10.
- Greenspan FS, Gardner DG. Basic and clinical endocrinology. 7th ed. New York: Lange Medical Books/McGraw-Hill; 2004. p. 238-41.
- DeGoot JL, Jameson LJ, Burger HG, Loriaux DL, Marshall JC, Odell WD. *Endocrinology T2*. Philadelphia: Saunders; 2001. p. 1430-32.
- Mickuvienė N, Krasauskienė A, Kazanavičius G. Atsitiktinai atrinktų jaunesniųjų klasių moksleivių skydliaukės ultragarsinio tyrimo duomenys. (The results of thyroid ultrasound examination in randomly selected schoolchildren.) *Medicina (Kaunas)* 2006;42(9):751-8.
- Jankauskienė J. Akiduobės uždegimai. (Orbital inflammations.) Kaunas: KMU; 2004. p. 134.
- Blužienė A, Jašinskas V, Barzdžiukas V, Benetienė G, Blužienė A, Butkienė A, et al. *Akių ligų vadovas*. (Manual of eye diseases.) Šiauliai: Narbuto A. S. leidykla; 2005.
- Zhang J, Lazer MA. The mechanism of action of thyroid hormones. *Annu Rev Physiol* 2000;62:439-66.
- Phillips SA, Rotman-Pikielny P, Lazar J, Ando S, Hauser P, Skarulis MC, et al. Extreme thyroid hormone resistance in a patient with a novel truncated TR mutant. *J Clin Endocrinol Metab* 2001;86(11):5142-47.
- Frank-Raue K, Lorenz A, Haag C, Höppner W, Boll HU, Knorr D, et al. Severe form of thyroid hormone resistance in a patient with homozygous/hemizygous mutation of T3 receptor gene. *Eur J Endocrinol* 2004;150:819-23.
- Kantaravičienė J, Barzdžiukas V, Kurapkienė S. Jaunų žmonių trumparegystės laipsnio ir akies matmenų ryšys. (Relationship between myopia degree and measurements of the eye among young people.) *Lietuvos bendrosios praktikos gydytojas* 2005;9(6):402-6.
- Vander JF, Gault JA. *Ophthalmology secrets*. Philadelphia: Hanley & Belfus, Inc; 2002.
- Jankauskienė J, Imbrasienė D. Sergančiųjų Greivso oftalmopatija akių pakitimų, išorinių akių raumenų storio ir akių judesių tyrimai. (Investigations of ocular changes, extraocular muscle thickness, and eye movements in patients with Graves' ophthalmopathy.) *Medicina (Kaunas)* 2006;42(11):900-3.
- Niewoehner CB. *Endocrine pathophysiology*. Madison: Fence Creek; 1998. p. 48.
- Vaughan D, Asbury T, Tabbara KF. *General ophthalmology*. 12th ed. Norwalk San Mateo: Appleton & Lange; 1989. p. 294-96.
- Saw SM, Chua WH, Hong CY, Wu HM, Chia KS, Stone RA, et al. Height and its relation to refraction and biometry parameters in Singapore Chinese children. *Investig Ophthalmol Vis Sci* 2002;43:1408-13.
- Drexler W, Findl O, Schmetterer L, Hitznberger C, Fercher A. Eye elongation during accommodation in humans: differences between emmetropes and myopes. *Investig Ophthalmol Vis Sci* 1998;39:2140-47.

Received 29 January 2008, accepted 4 May 2009
Straipsnis gautas 2008 01 29, priimtas 2009 05 04