

Automatic Identification of Diabetic Macular Edema Using a Transfer Learning-Based Approach [†]

Joaquim de Moura ^{1,2,*} , Plácido L. Vidal ^{1,2} , Jorge Novo ^{1,2}  and Marcos Ortega ^{1,2} 

¹ Department of Computing, University of A Coruña, 15071 A Coruña, Spain

² CITIC—Research Center of Information and Communication Technologies, University of A Coruña, 15071 A Coruña, Spain

* Correspondence: joaquim.demoura@udc.es; Tel.: +34-981-167-000 (ext. 1330)

[†] Presented at the 2nd XoveTIC Conference, A Coruña, Spain, 5–6 September 2019.

Published: 31 July 2019



Abstract: This paper presents a complete system for the automatic identification of pathological Diabetic Macular Edema (DME) cases using Optical Coherence Tomography (OCT) images as source of information. To do so, the system extracts a set of deep features using a transfer learning-based approach from different fully-connected layers and different pre-trained Convolutional Neural Network (CNN) models. Next, the most relevant subset of deep features is identified using representative feature selection methods. Finally, a machine learning strategy is applied to train and test the potential of the identified deep features in the pathological classification process. Satisfactory results were obtained, demonstrating the suitability of the presented system to filter those pathological DME cases, helping the specialist to optimize their diagnostic procedures.

Keywords: Computer-Aided Diagnosis; Optical Coherence Tomography; Diabetic Macular Edema; Convolutional Neural Network

1. Introduction

Diabetic Macular Edema (DME) is one of the most prevalent causes of visual loss and blindness in industrialized countries, representing a concerning public health problem. Optical Coherence Tomography (OCT) is a non-invasive diagnostic technique that provides a high-resolution cross-sectional view of the retina, being commonly used for the diagnosis, monitoring and treatment of the DME disease [1,2]. In this way, a precise and automatic classification of OCT scans between normal or pathological DME cases allows the clinical specialists to make a more accurate diagnosis and treatment of this relevant ocular disease. Figure 1 shows representative examples of OCT scans with and without the presence of DME where we can observe a considerable level of deterioration of the main retinal tissues and the consequent thickening of the retina.

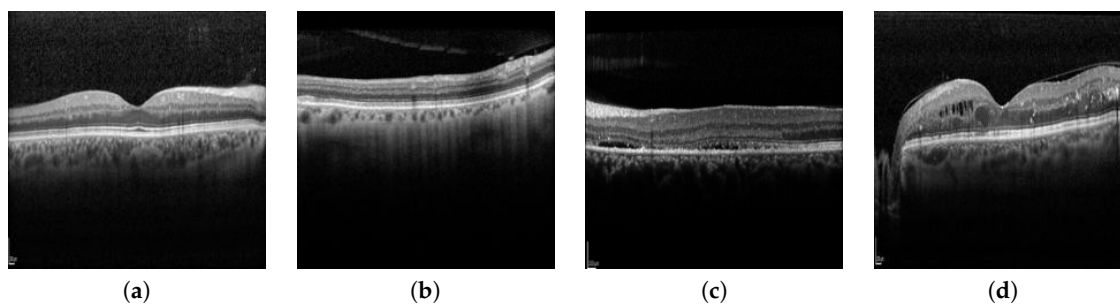


Figure 1. Representative examples of OCT scans. (a,b) OCT scans without the presence of DME. (c,d) OCT scans with the presence of DME.

2. Methodology

The presented methodology receives, as input, a set of cross-sectional OCT scans centered in the macular region of the retina. As illustrated in Figure 2, the designed pipeline is composed by 3 main stages. Firstly, the method extracts a set of deep features from the OCT scans using a transfer learning-based approach from different fully-connected layers and different pre-trained Convolutional Neural Network (CNN) models [3]. Then, the method identifies the most relevant subset of deep features using different feature selection approaches. Then, a machine learning strategy is applied to generate a classification model. Finally, the method presents, as output, a labelled OCT image with the classification between normal or pathological DME cases.

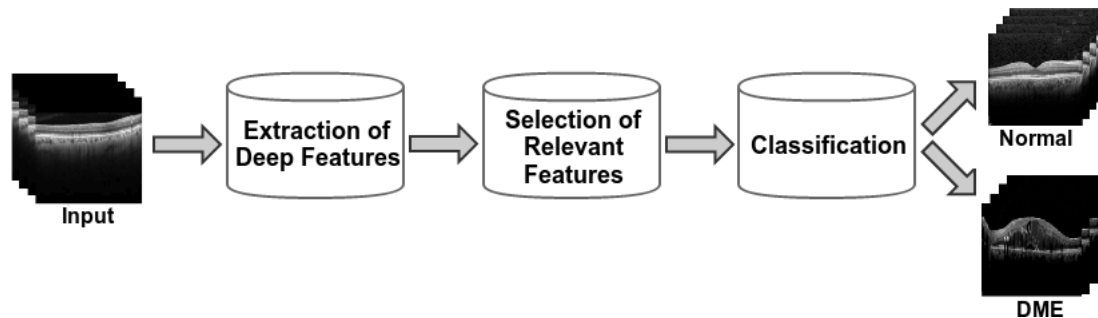


Figure 2. Main structure of the proposed methodology.

3. Results and Conclusions

In this paper, we propose a complete methodology for the automatic identification of pathological DME cases using the OCT images as source of information. Satisfactory results were obtained, demonstrating the suitability of the presented system and consequently helping the clinical specialists in their diagnostic procedures, reducing healthcare costs and improving the quality of life of patients with diabetes.

Author Contributions: J.d.M., P.L.V. and J.N. contributed to the analysis and design of the computer methods and the experimental evaluation methods. J.N. and M.O. contributed with domain-specific knowledge. All the authors performed the result analysis. J.d.M. was in charge of writing the manuscript, and all the authors participated in its critical revision and final approval.

Funding: This work is supported by the Instituto de Salud Carlos III, Government of Spain and FEDER funds through the DTS18/00136 research project and by Ministerio de Ciencia, Innovación y Universidades, Government of Spain through the DPI2015-69948-R and RTI2018-095894-B-I00 research projects. Also, this work has received financial support from the European Union (European Regional Development Fund—ERDF) and the Xunta de Galicia, Centro singular de investigación de Galicia accreditation 2016–2019, Ref. ED431G/01; and Grupos de Referencia Competitiva, Ref. ED431C 2016-047.

Conflicts of Interest: The authors declare no conflict of interest.

References

1. Samagaio, G.; Estévez, A.; de Moura, J.; Novo, J.; Fernández, M.; Ortega, M.; Automatic macular edema identification and characterization using OCT images. *Comput. Methods Programs Biomed.* **2018**, *163*, 47–63.
2. Vidal, P.L.; de Moura, J.; Novo, J.; Penedo, M.G.; Ortega, M. Intraretinal fluid identification via enhanced maps using Optical Coherence Tomography images. *Biomed. Opt. Express* **2018**, *9*, 4730–4754.
3. De Moura, J.; Novo, J.; Ortega, M. Deep Feature Analysis in a Transfer Learning-based Approach for the Automatic Identification of Diabetic Macular Edema. In Proceedings of the 2019 International Joint Conference on Neural Networks (IJCNN), Budapest, Hungary, 14–19 July 2019; pp. 1–8.

